**MEDICAL EMERGENCIES IN DENTAL PRACTICE: A REVIEW****Siddharth Tevatia*¹, Vaibhav Mukund², Shivam Agarwal³ and Vivek Shah⁴**¹Post Graduate Student, Department of Periodontology & Oral Implantology, ITS CDSR.^{2,3,4}Post Graduate Student, Department of Oral & maxillofacial Surgery & Oral Implantology, ITS-CDSR.

Article Received on 25/05/2016

Article Revised on 16/06/2016

Article Accepted on 05/07/2016

Corresponding Author*Dr. Siddharth Tevatia**Post Graduate Student,
Department of
Periodontology & Oral
Implantology, ITS CDSR
Muradnagar, Ghaziabad-
2012016.**ABSTRACT**

Every dental practitioner needs a knowledge of the diagnosis and management of medical emergencies. Medical emergencies in dental practice are uncommon but could occur at any time. It is important, however, that dental practitioners are proficient in recognizing them and carrying out initial management of such emergencies.

KEYWORDS: *Dental; Emergencies; Syncope; Hypersensitivity.***INTRODUCTION**

Life threatening emergencies can and do occur in the practice of dentistry. They can happen to anyone a patient, a doctor, a member of the office staff or a person who is merely accompanying a patient. The occurrence of life threatening emergencies in dental office is infrequent, many factors can increase the likelihood of such incidents.^[1] These include increasing number of old persons seeking dental care, therapeutic advances in the medical profession, growing trend towards longer dental appointments and increasing use and administration of drugs in dentistry. Emergencies can sometimes be anticipated as a result of having obtained a thorough medical history.^[2] More than 54 percent of the emergencies occurred during or right after local anesthesia. The types of treatments cited with the greatest percentage of emergencies are two procedures associated with potential high patient anxiety tooth extraction and pulp extirpation.^[3] It is important to recognize and diagnose what is happening in order to manage the particular emergency appropriately. Dental practitioners and their staff need to have appropriate skills, training and equipment available to deal with potentially life threatening conditions.^[4,5] These emergencies range from the minor such as

the common faint [vaso-vagal syndrome] and hyperventilation, to the life-threatening such as anaphylaxis.

Most frequently occurring medical emergencies that develop during the course of dental treatment are as follows.

Vasovagal syncope

Postural hypotension

Allergies/ Hypersensitivity reactions

Acute Adrenal Insufficiency

Diabetic emergencies

Hyperventilation

Asthma- Status Asthmaticus

Cardiac chest pain-Myocardial infarction

Epilepsy- Status Epilepticus

VASOVAGAL SYNCOPE (Common Faint)

More often referred to as common faint is a benign and self limiting process that if not managed correctly is life threatening.^[1] It is a reflex which is mediated by autonomic nerves, leading to widespread vasodilatation in the splanchnic and skeletal vessels, and bradycardia resulting in diminished cerebral perfusion. In surveys of medical emergencies in dental offices, vasodepressor syncope was the most common medical emergency situation reported, accounting for approximately 53% of all reported emergencies.^[1]

Syncope in a dental office can be precipitated due to psychogenic or non psychogenic factors. Psychogenic which includes fright, anxiety, emotional stress, and receipt of unwelcome news and the non psychogenic factors include hunger from dieting or missing meals erect sitting or standing posture.^[1] The risk of syncope is greatly increased in an apprehensive patient who is either standing or seated upright during treatment.

Clinical presentation

Patient takes on a death like appearance.^[1] Often patients exhibits brief episodes of convulsive activity that can be mistakenly viewed as primary seizure.^[6] Heart rate of less than 60 beats per minute and blood pressure to an extremely low level of 30/15mm Hg is seen in a patient of syncope.^[1]

Proper management of vasodepressor syncope follows the basic management recommended for all unconscious patients.

P- POSITION

A-AIRWAY

B- BREATHING

C- CIRCULATION

Position: As soon as consciousness is recognized, the victim should be placed in supine (horizontal) position with the brain at the same level as the heart and feet elevated slightly (10-15 degree angle). The rescuers should avoid head down (Trendelenberg) position because gravity forces the abdominal viscera superiorly up into the diaphragm, thus restricting movement and diminishing the effectiveness of breathing.^[7]

Airway, Breathing, Circulation: Victim must be assessed immediately and a patent airway must be ensured. In most instances of vasodepressor syncope, Head Tilt-Chin Lift procedure successfully establishes a patent airway. Research conducted during the past 20 years has provided evidence that the head tilt chin lift procedure is the most consistently reliable airway.^[8]

To maintain the airway by using Head Tilt Chin Lift procedure the fingers of one hand of the rescuer should be placed under the bony symphysis region of the victim's mandible to lift the tip of the mandible up and bring the chin forward, because the tongue is attached to the mandible, it is pulled forward and off the posterior wall of the pharynx.(figure 1) Head should be extended sufficiently to lift the tongue and establish a patent airway but to avoid overextension of the head which will increase the risk of possible damage to victim's vertebrae and spinal cord.^[1]

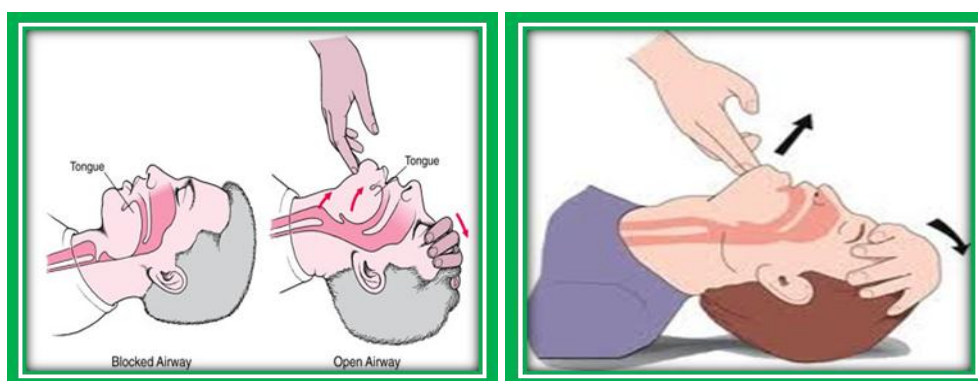
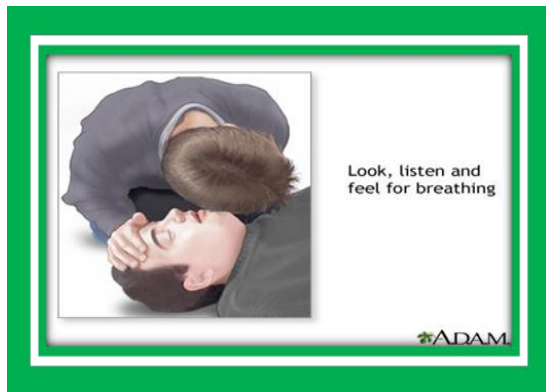

Figure 1

Assessment of airway patency and adequacy of breathing

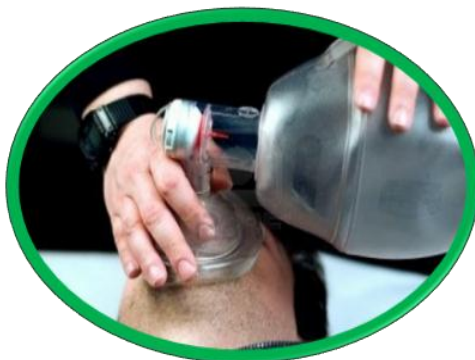

'Look, Listen and Feel' technique in which the rescuer leans over the victim, by placing his or her ear 1 inch from the nose and mouth while looking towards the victim's chest for spontaneous respiratory movements.(figure 2)

Figure 2

However artificial ventilation may be necessary on few occasions where spontaneous breathing ceases.

Mouth to mouth ventilation: the rescuer's hand should be placed on the victim's forehead to maintain the backward tilt while the rescuer's thumb and index fingers pinch the victim's nostrils closed. With mouth wide open, the rescuer should take a deep breath, make a tight seal around victim's mouth and blow into the mouth.^[1] The first cycle of ventilation consist of 2 full breaths, with the rescuer allowing 2 seconds per inspiration, taking a breath after each ventilation. Exhalation occurs passively when the rescuer's mouth is removed from the victim's, allowing gravity to deflate the lungs.

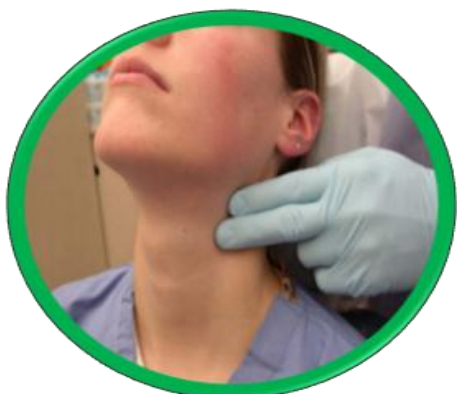

Bag valve mask devices (Figure 3) such as Ambu Bag and pulmonary manual resuscitator can be used which provide less ventilatory volume than mouth to mouth or mouth to nose technique and hence should be used only by well trained and experience personnel only.^[9]

Figure 3

Circulation: Several sites are available for recording the heart rate including the brachial arteries and radial arteries in the arm and carotid arteries in the neck. However when the patient is unconscious and particularly when respiratory movements are absent, the carotid artery is the most reliable indicator of cardiovascular function of an adult. If the victim is a

child of 1-8 years ,the carotid artery is used while for a infant (< 1 year) the brachial artery or femoral artery is recommended.^[10]



Carotid artery palpation-The rescuer should place the hand supporting the victim's chin onto the thyroid cartilage. On the side on which the rescuer is positioned, the fingers should slide into the groove between the victim's thyroid cartilage and sternocleidomastoid muscle band in the neck. The carotid artery is located in this groove.^[1](figure 4)

Figure 4

Definitive care- administration of oxygen

Monitoring of vital signs

Additional procedures like loosening of clothes, ties and collars. Use of aromatic ammonia^[1]



POSTURAL HYPOTENSION

Also known as orthostatic hypotension, is a second leading cause of transient loss of consciousness in dental settings. A drop in systolic pressure of 30 mm Hg or greater or a 10 mm Hg or greater fall in diastolic pressure that occurs on standing.^[11] In a dental office patients may remain recumbent for treatment lasting as long as 2-3 hours. In these circumstances, postural hypotension may develop when the dental chair is returned quickly to the upright position or the patient stands.

Many factors have been identified as causes of postural hypotension

Administration and ingestion of drugs^[12]

Prolonged period of recumbency or convalescence^[13]

Inadequate postural reflex

Late stage pregnancy

Clinical presentation: patients experience precipitous drop in blood pressure and lose consciousness whenever they stand or sit upright. These patients lose consciousness rapidly, or merely become lightheaded or develop blurred vision but not actually lose consciousness.^[1]

Management

Position: unresponsive patient is placed into supine position with the feet slightly elevated.

Airway, Breathing, Circulation: Head tilt–chin lift procedure is usually successful. look listen feel technique should be used to detect any obstruction to breathing and the carotid pulse should be palpated to determine adequacy of circulation.^[1]

Definitive care: If the patient is conscious, or unconscious yet spontaneously breathing, oxygen should be delivered by a full face mask, where a flow rate of 6 to 10 liters per minute is appropriate for most adults. If the patient is unconscious and apneic, it should be delivered by a bag-valve-mask device where a flow rate of 10 to 15 liters per minute.^[14]

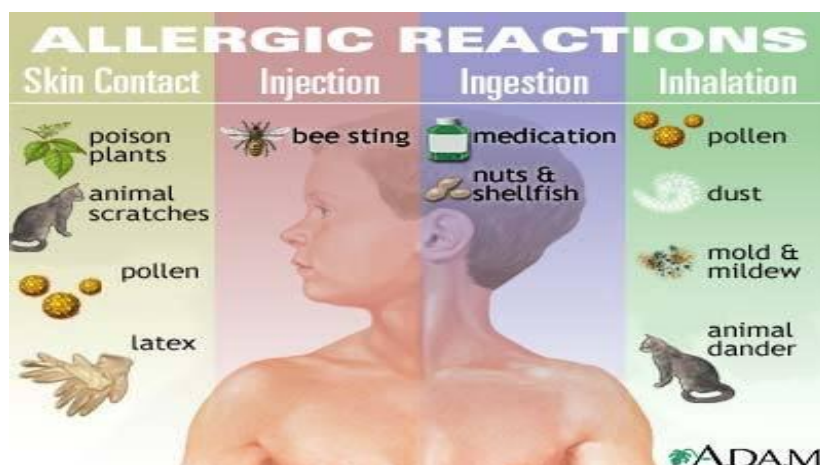Monitoring of vital signs

Subsequent management—changes from supine to upright must occur slowly. The patient should be repositioned approximately 22.5 degrees with sufficient time for accommodation before being raised to approximately 45 degrees. Patient should be then raised to about 67.5 degrees before finally being raised to 90 degrees.^[1]

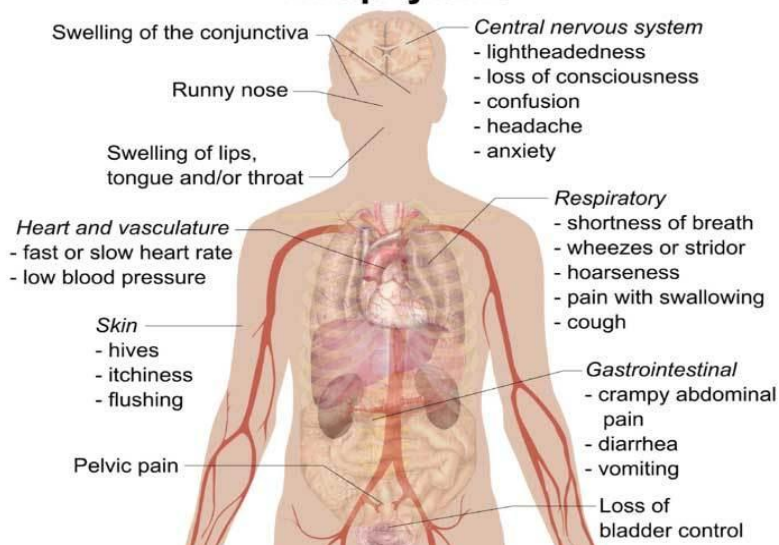
ALLERGY /HYPERSENSITIVITY REACTIONS

Allergy is a hypersensitive state acquired through exposure to a particular allergen, re-exposure to which produces a heightened capacity to react. A patient's history is a major factor in determining the risk of allergy, the specific drug to be employed is of extreme importance. Antibiotics like penicillin or sulfonamides, analgesics like codeine and ester containing local anesthetics like procaine, tetracaine provoke allergic response very frequently.^[1]

Anaphylaxis is a Type 1 hypersensitivity reaction involving IgE to which free antigen binds leading to the release of vasoactive peptides and histamine.



Signs and symptoms of Anaphylaxis



Management of a patient with suspected anaphylaxis during anesthesia

Stop administration of all agents likely to cause anaphylaxis.

P- Position- the patient should be placed flat with legs elevated.

A-B-C- Airway, Breathing, Circulation.

Definitve care: Epinephrine intramuscularly (IM) 0.3 -0.5mg of 1:1000 dilution in the anterolateral aspect of the thigh. Repeat it every 10 minutes should be administered.^[1]

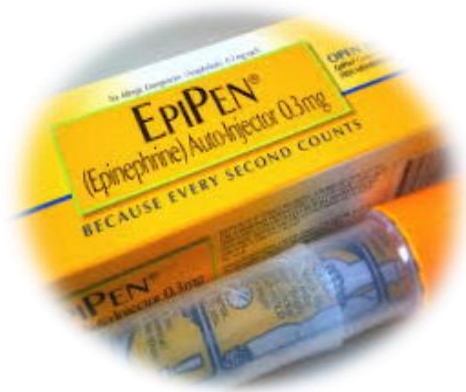If the patient is conscious, or unconscious yet spontaneously breathing, oxygen should be delivered by a full face mask, where a flow rate of 6 to 10 liters per minute is appropriate for

most adults. If the patient is unconscious and apneic, it should be delivered by a bag-valve-mask device where a flow rate of 10 to 15 liters per minute.^[14]

Monitor vital signs

Additional drug therapy- histamine blocker- diphenhydramine (50 mg for adults, 25 mg for children) IM/IV or chlorpheniramine 10-20 mg by slow IV infusion) should be administered.^[1]

corticosteroid – 100-500 mg hydrocortisone slowly IV should be given.^[1]



Epi pen (epinephrine auto injector 0.3 mg)

Many patients with a history of anaphylactic reactions will carry an ‘Epipen’, which contains 300 micrograms of epinephrine. This may be used if such a patient has an anaphylactic reaction in the dental surgery

ACUTE ADRENAL INSUFFICIENCY

a life threatening situation was first recognised by Addison in 1844 thus primary adrenal insufficiency is called Addison’s disease, an insidious and usually progressive condition.^[15] The incidence of Addison’s disease is estimated as 0.3 to 1 case per 100,000 individuals, occurs equally in both sexes and among all age groups including infants and children resulting from sudden withdrawal of steroid hormones.^[16] Sudden withdrawal of steroid hormones from a patient with normal adrenal cortices but with a temporary insufficiency resulting from cortical suppression through prolonged exogenous glucocorticoid administration leads to secondary insufficiency leading to hypotension, shock and death. It may be precipitated by stress, trauma, surgery or infection.

Criteria for determining adrenal insufficiency^[1]

- ✓ History of current or recent long term steroid use
- ✓ Mental confusion
- ✓ Nausea, vomiting
- ✓ Abdominal pain
- ✓ Hypotension

Management

- Step 1- recognition of unconsciousness is determined by lack of response.
- Step 2- **Position**- patient should be placed supine with legs elevated.^[1]
- Step 3-**A-B-C**- Head Tilt-Chin Lift procedure and assessment of Airway, Breathing Circulation should be implemented.^[1]
- Step 4- 100 mg of hydrocortisone(glucocorticoid) via IV should be administered over 2 hours, if unavailable IM administration of 100 mg hydrocortisone can be used.^[1]
- Step 5- IV infusion of 1 l normal saline or 5% dextrose solution should be administered over 1 hour while awaiting emergency assistance.^[1]
- Step 6- patient should be then transferred to the hospital.

DIABETIC EMERGENCIES

Diabetes is the most common endocrine disease.^[17] Approximately 135 million individuals worldwide and 20.8 million Americans have diabetes mellitus.

Hypoglycemic shock or the insulin shock develops rapidly especially in patients receiving injectable insulin therapy who may lose consciousness within minutes after insulin administration. Common causes of hypoglycemia are omission or delay of meals, excessive exercise before meals or increasing insulin dosage.

Although hyperglycemia does not by itself usually lead to an acute, life threatening emergency, if left untreated it may progress to diabetic ketoacidosis and subsequent diabetic coma, both of which are life threatening.^[1]

A dentist in general practice is much more likely to encounter hypoglycemia than hyperglycemia since the latter has a much slower onset.

The signs and symptoms of hypoglycemia include.^[18]

- ✓ Trembling
- ✓ Hunger;
- ✓ Headache;
- ✓ Sweating;
- ✓ Slurring of speech;
- ✓ 'Pins and needles' in lips and tongue;
- ✓ Aggression and/or confusion;
- ✓ Seizures;
- ✓ Unconsciousness.

Management

Step 1 – the ongoing dental procedure should be terminated

Step 2- Patient should be placed supine with legs elevated

Step3 – Airway, breathing, circulation are assessed

Step4 – Definitive Care

- ✓ IV injection of 50% dextrose solution or IM injection of 1 mg glucagon is administered. Unconscious patient must never receive via mouth any liquid or other substance that run through the throat – airway obstruction^[1]
- ✓ If neither glucagon nor dextrose solution are available , 0.5 mg of 1:1000 epinephrine concentration may be administered subcutaneously or IM route and repeated every 15 minutes.^[1]
- ✓ In the absence of parental route or drugs a thick paste of concentrated glucose may be used with a high degree of safety.^[1]
- ✓ A small amount of honey or syrup may be placed in patient's buccal fold.^[1]
- ✓ Once individual is conscious , oral carbohydrates such as fruit juice or soft drinks may be administered.^[1]
- ✓ Once stabilized patient is transported to hospital.

HYPERVENTILATION

A common emergency occur in the dental office, almost always is a result of extreme anxiety. However organic causes for hyperventilation do exist; these include pain, metabolic acidosis, drug intoxication, hypercapnia, cirrhosis and organic central nervous system disorders.^[19]

At the onset of hyperventilation which is frequently precipitated by the fear associated with receiving a local anesthetic injection, the patient may report with chest tightness and a feeling of suffocation, light-headedness; dizziness; weakness, paraesthesia, chest pain and/or palpitations; breathlessness. Respiratory changes are the primary concern which may exceed to 25- 30 breaths per minute. Patient also exhibits increase in the depth of breathing.

Management^[1]

- ✓ Presumed cause of the episode should be removed from the patient's line of vision.
- ✓ The preferred position for a hyperventilating patient is usually upright. The supine position is normally uncomfortable for such patients because of the diminished ventilator volume caused by the impingement of the abdominal viscera on the diaphragm.

- ✓ All foreign objects such as rubber dam, clamps, and partial dentures should be removed.
- ✓ Patient should be calmed by reassuring and should be helped to regain control of breathing by speaking calmly and breathing slowly and regularly at a rate of 4 to 6 breaths per minute.
- ✓ In order to correct respirator alkalosis, the most practical method is by instructing the hyperventilating patient to cup their hands in front of their mouth and nose and to breathe in and out of the reservoir of carbon dioxide enriched exhaled air.
- ✓ Parenteral drug administration in order to relieve anxiety are benzodiazepines, diazepam, midazolam intravenously. When intravenous route is unavailable, 10 mg diazepam or 3-5 mg midazolam may be administered intramuscularly.
- ✓ Once the episode of hyperventilation is ended with all clinical signs and symptoms resolved, the dentist must determine the cause of hyperventilation. Dental treatment may continue at this time if both the doctor and the patient are comfortable in doing so.

STATUS ASTHMATICUS

Asthma was defined in 1830 by Eberle, a Philadelphia physician, as “paroxysmal affection of the respiratory organs, characterized by great difficulty of breathing, tightness across the breast, and a sense of impending suffocation, without fever or local inflammation.”^[20] Approximately 17 million Americans, and more than 100 million persons worldwide suffer from asthma.^[21]

Status asthmaticus is the most severe clinical form of asthma. It is a clinical state in which a patient with moderate to severe obstruction does not respond significantly to the rapid acting beta adrenergic agents.

Individuals who suffer from status asthmaticus experience wheezing, dyspnea, hypoxia and other symptoms that are refractory to two or three doses of beta adrenergic agents.^[22] Also signs of extreme fatigue, dehydration, severe hypoxia cyanosis peripheral vascular shock and drug intoxication as a result of intensive pharmacological therapy.^[23] If not managed adequately and promptly, the patient may die as a result of respiratory changes like hypotension, respiratory acidosis, that develop secondary to respiratory distress.

Management

- ✓ The doctor should be able to recognize the problem (respiratory distress or wheezing)
- ✓ The ongoing dental treatment should be discontinued.

- ✓ Patient should be positioned comfortably usually upright
- ✓ Airway, breathing, circulation should be assessed.
- ✓ Oxygen should be administered through a full face mask, nasal hood or nasal canula. If a nasal canula is used, a flow of 5-7 L per minute is adequate.^[1]
- ✓ Hydrocortisone hemisuccinate 100mg (or equivalent dose of another glucocorticoid)i.v. stat,followed by 100-200 mg 4-8 hourly infusion; may take upto 6 hours to act.^[24]
- ✓ Nebulised salbutamol (2.5-5 mg) plus ipatropium bromide (0.5 mg) intermittent inhalations driven by oxygen.^[24]
- ✓ Salbutamol/Terbutaline 0.4 mg i.m./s.c. may be added ,since inhaled drug may not reach smaller bronchi due to severe narrowing /plugging.^[24]
- ✓ Intubation / mechanical ventilation should be done if needed.
- ✓ Dehydration and acidosis can be corrected with saline + sodium bicarbonate /lactate infusion.^[24]

Following resolution, the dentist can discharge the patient from the dental office if the doctor believes that the patient is in stable condition.

CHEST PAIN OF CARDIAC ORIGIN.

Most patients who suffer chestpain from a cardiac origin in the dental surgery are likely to have a previous history of cardiac disease. It is important that the patient has taken his/her normal medication on the day of the appointment. The pain of myocardial infarction (MI) will often be similar to that of angina but more severe and, unlike angina, will not be relieved by GTN (glyceryl trinitrate).^[18]

Patient of Myocardial Infarction presents with Severe, crushing chest pain which may radiate to the shoulders and down the arms (particularly the left arm) and into mandible The skin becomes pale and clammy, Shortness of breath; Pulse becomes weak and patient may become hypotensive; Often there will be nausea and vomiting.^[18]

Management

Patients will be best managed in the sitting position

Patients who feel faint should be laid flat

High flow oxygen (10 litres per minute) should be administered.

Sublingual Glyceryl trinitrate spray(0.4 mg tablets ,1 tablet very 5 minutes upto three doses.) should be given.

300 mg aspirin should be given orally to be chewed (if no allergy)

If the patient is still unresponsive, the practitioner should check for 'signs of life' (breathing and circulation) and start Cardiopulmonary Resuscitation.^[18]

STATUS EPILEPTICUS

Is defined as continuous clinical or electrical seizure activity or repetitive seizures with incomplete neurologic recovery interictally for a period of at least 30 minutes.^[25] In the dental office environment, the definition of the Academy of Orthopaedic Surgeons may be more practical, defining status epilepticus as a seizure that continues for more than 5 minutes or a repeated seizure that begins before the individual recovers from the initial episode.^[26] The incidence of status epilepticus among epileptic patients is about 5%, although the reported range varies from 1.3% to 10%.^[27] The most common factor precipitating status epilepticus is failure of the epileptic patient to take antiepileptic drugs.

The signs and symptoms of epilepsy include:

The patient may have an 'aura' or premonition that a seizure is about to occur;

Tonic phase – loss of consciousness patient becomes rigid and falls and becomes cyanosed;

Clonic phase – jerking movements of the limbs, tongue may be bitten;

Frothing at the mouth, urinary incontinence

Management of a patient of epilepsy

The "aura" of the patient should be recognized and the ongoing dental treatment should be discontinued.

Patient should be placed in supine position with feet elevated.

Airway, Breathing, circulation should be maintained.

No attempt should be made to hold the patient's extremities in a fixed position because of the risk of bony fractures.^[26]

The head must be protected from traumatic injury through placement of a thin, soft item (blanket or jacket) beneath the head, ensuring that the head is not flexed forward, obstructing the airway. The headrests on most dental chairs are normally well padded so that no additional protection is necessary for the head. Any additional pillow or doughnut device should be removed. Removing the head rest permits extending the neck, lifting the tongue and creating greater airway patency.

The forcible placement of objects into patient's mouth doesn't improve airway maintainence. Indeed the patient's muscle of mastication are in tetany during the seizure, and the patient; mouth must be forced open, greatly increasing the risk of injury to both soft and hard tissues. Teeth have been fractured and aspirated during these attempts to help seizing patients.^[28]

The decision to give medication should be made if seizures are prolonged (with active convulsions for 5 minutes or more (status epilepticus) or seizures are occurring in quick succession). If possible, high flow oxygen should be administered. The possibility of the patient's airway becoming occluded should constantly be remembered and the airway must therefore be protected.

Diazepam 10 mg i.v. bolus injection (2 mg /min) followed by fractional doses every 10 minutes or slow infusion titrated to control the fits.

Phenobarbitone (100-200 mg i.m. /i.v.) or phenytoin (25-50 mg/min in a running saline i.v. line).

The i.v. admistration of 25- 50 ml of dextrose solution is recommended to rule out hypoglycemia.

All patients with tonic –clonic seizure requires hospitalization after the episode for neurological evaluation and initiation of a treatment protocol to minimize further episodes.

PREVENTION

Every dental office should have an emergency kit. Commercially available kits are expensive and contain drugs and equipment that will never be used; in fact, some of these kits contain drugs that have not been used in general medicine for twenty years. A kit can very easily- and inexpensively- be assembled, although the actual drugs in the kit should be selected by the dentist. Never include drugs or equipment that the dentist is not trained to use or comfortable in administering. Drugs can be purchased from a hospital pharmacy and the other supplies obtained from a local medical equipment company.

Equipment

- Oxygen cylinder with masks and cannulas
- Large bore suction tips
- Oral airways (small, medium, large)

- Pocket mask
- Blood pressure cuff and stethoscope
- Laryngoscope and Magill forceps
- Instant glucose or sugar packets

Drugs

- Aspirin 81 mg Chewable tablets (Children's Aspirin)
- Epinephrine 1:1000 prefilled syringe or EpiPen[®] Auto-Injector
- Diphenhydramine (Benadryl[®]) 50 mg prefilled syringe or 50 mg tablets
- Nitroglycerin (Nitrostat[®]) 0.4 mg tablets or spray (Nitrolingual[®] Spray)

CONCLUSION

Medical emergencies, whatever is the cause, must be recognized quickly and managed effectively. After correct diagnosis, prompt appropriate management will deal with medical emergencies effectively. It is important that each member of the dental team knows what his/her role should be in the event of a medical emergency. Training should be updated regularly and at least on annual basis. Medical emergencies cannot be prevented completely, a staff that can render appropriate assistance to a patient can increase the chances of patient survival.

REFERENCES

1. Malamed SF: Medical Emergency in the Dental Office, 6th Edition. Mosby, 1997.
2. Shampain GS. Patient assessment and preventive measures for medical emergencies in the dental office, *Dent Clin N Am.*, 1999; 43: 383–400.
3. Malamed SF: Managing medical emergencies, *JADA.*, 1993; 124: 40-53.
4. Broadbent, J.M., Thomson, W.M: The readiness of New Zealand General Dental Practitioners for Medical Emergencies *NZDJ.*, 2001; 97: 82-86.
5. Zacharias, M., Hunter, K. Mac D: Cardiopulmonary Resuscitation in Dental Practice – an update. *NZDJ.*, 1994; 90: 60-65.
6. Deihl RR, Linden D: Images in clinical medicine : neurocardiogenic syncope, *N Engl J Med.*, 1998; 339: 312.
7. Erie JK: Effect of position on ventilation .In: Faust RJ ,Editor :Anesthesiology review, New York, Churchill Livingstone., 1991.
8. Melkar R: Recommendations for ventilation during cardiopulmonary resuscitation: time for change? *Crit Care Med.*, 1985; 13: 882.

9. American Heart Association in Collaboration on Resuscitation with the International Liason Committee on Reuscitation (ILCOR): Guidelines for cardiopulmonary resuscitation and emergency cardiovascular care, *Circulation.*, 2000; 102: 384.
10. Cavallaro D, Melkar R: Comparison of two techniques for determining cardiac activity in infants, *Crit Care Med.*, 1983; 14: 189-190.
11. Consensus statement on the definition of orthostatic hypotension, pure autonomic failure and multiple system atrophy, *J Neurol Sci.*, 1996; 144: 218-219.
12. Atkins D, Hanusa B, Sefeik T, Kapoor W: Syncope and orthostatic hypotension, *Am J Med.*, 1991; 91: 179-185.
13. Akhtar M, Jazayeri M, Sra J: Cardiovascular causes of syncope; identifying and controlling trigger mechanism, *Postgrad Med.*, 1991; 90: 87-94.
14. Daniel A Haas: Medical Emergencies in the Dental Office: Conditions in Each Country, the Extent of Treatment by the Dentist, *J Am Dent Assoc.*, 2006; 53: 20-24.
15. Vallotton MB: Endocrine emergencies: disorders of adrenal cortex, *Baillieres, Clin Endocrinol Metab.*, 1992; 6: 41-56, 1992
16. Oelkers W: Adrenal insufficiency, *N Engl J Med.*, 1996; 335: 1206-1212.
17. Cydulka RK, Siff J: Diabetes mellitus and disorders of glucose homeostasis. In: Marx JA, Hockberger RS, Walls RM, editors: *Rosen's emergency medicine: concepts and clinical practice.*, 2002; 5: 1635-1664.
18. Greenwood M: Medical Emergencies in Dental Practice: 2. Management of Specific medical Emergencies, *Dent Update.*, 2009; 36: 262–268.
19. Dailey RH: Difficulty in breathing. In: Schwartz GR: *Principles and practice of emergency medicine*, Philadelphia, 1992.
20. Eberle J: *A treatise on the practice of medicine*, Philadelphia, John Grigg, 1830.
21. Kemp JP: Recent advances in the management of asthma using leukotriene modifiers, *Am J Respir Med.*, 2003; 2: 139-156.
22. Soler M, Imhof E, Perruchoud AP: Severe acute asthma: pathophysiology, clinical assessment and treatment, *Respiration.*, 1990; 57: 114-121.
23. Groneberg DA, Wagner U, Chung KF: Mucus and fatal asthma, *Am J Med.*, 2004; 116: 66-67.
24. Tripathi KD: Drugs for bronchial asthma. In Tripathi KD editor: *Essentials of Medical Pharmacology*, 6th Edition, 2008; 227.
25. Foldvary-Schaefer N, Wyllie E: Epilepsy. In: Goetz CG, editor: *Textbook of clinical neurology ed 2*, Philadelphia, WB Saunders, 2003; 1059-1088.

26. American Academy of Orthopaedic Surgeons: Emergency care and transportation for the sick and injured, ed 4, Orco, IL, American Academy of Orthopaedic Surgeons, 1987.
27. Young GB: Status Epilepticus and brain damage: pathology and pathophysiology, *Adv Neurol.*, 2006; 97: 217-220.
28. Scheuer ML, Pedley TA: The evaluation and treatment of seizures, *N Engl J Med.*, 1990; 323: 1468-1474.