

THE CLINICAL SPECTRUM OF PITIRIASIS ROSEA IN BAQUBA CITY

Dr. Abdul Jabbar Yassin Al-Zubaidy¹, Dr. Alaa Aldeen Khorsheed*² and Dr. Wathik M. Alshamary³

¹M.B.Ch.B. D.V.D. Baquba Teaching Hospital, Baquba, Diyala, Iraq.

²M.B.Ch.B. D.V.D. F.I.B.M.S. Dermatol. Baquba Teaching Hospital, Baquba, Diyala, Iraq.

³M.B.Ch.B. F.I.B.M.S. Dermatol. Baquba Teaching Hospital, Baquba, Diyala, Iraq.

*Corresponding Author: Dr. Alaa Aldeen Khorsheed

M.B.Ch.B. D.V.D. F.I.B.M.S. Dermatol. Baquba Teaching Hospital, Baquba, Diyala, Iraq.

Article Received on 08/04/2018

Article Revised on 29/04/2018

Article Accepted on 20/05/2018

ABSTRACT

Background: Pityriasis rosea is an acute, benign, self-limiting, disorder that most commonly affects teenagers and young adults. The eruption has a characteristic pattern. It is a mild inflammatory exanthema characterized by Salomon-colored papular and macular lesions usually preceded by herald patch. **Aim of the study:** The aim of this study to evaluate the clinical pattern of pityriasis rosea in Baquba city. **Patients and methods:** A total number of one hundred patients with various degree of severity, types and distribution of pityriasis rosea were seen in the outpatients clinic department of dermatology in Baquba Teaching hospital, Diyala, Iraq. From January 2017 to October 2017. All patients examined thoroughly to determine the site, shape, severity of the lesions. **Result:** A total number of 100 patients aged from 9 months to 63 years with mean age of 21years.52 males' 48 females' patients, Most age group between 11-20 years, The herald patch was present in only 67 patients. 72%of secondary lesion was scaly erythematous lesion,22% of patients pityriasis preceded by flu like illness.66%had mild itching.

KEYWORDS: Pityriasis rosea, Baquba.

INTRODUCTION

Pityriasis rosea (PR) is a papulosquamous disorder first described by Robert Willan in 1798 but under another terminology.^[1]

PR is an acute, benign, self-limiting, disorder that most commonly affects teenagers and young adults. The eruption has a characteristic pattern.^[2] It is a mild inflammatory exanthema characterized by Salomon-colored papular and macular lesions that are first discrete but may become confluent. The individual patches are oval or circinate and converted with finely crinkled, dry epidermis, which often desquamates leaving a collarate of scaling when stretched across the long axis, the scales tend to fold across the lines of stretch.^[3] Its distinguishing clinical characteristics are the presence of an initial red scaling patch (herald patch) followed 7-14 days by a more generalized eruption on the non-sun-exposed areas of the body. The disease is frequently asymptomatic, although pruritus may be present in few patients. P R can occur throughout the year, but more commonly is observed during the autumn and spring,^[4]

The incidence is highest between age 15 and 40 and women are more frequently affected than men.^[2] The lesions are distributed mainly on the trunk and proximal limbs, however, the secondary skin eruptions may also

present on the face and extremities.^[5] Mucous membrane lesions occur in 16% of all PR cases, but due to lack of symptoms, these oral lesions are often overlooked and are rarely recorded.^[6] an exact cause for this has not been found.^[7] But various hypotheses have been postulated; incriminating infective agents such as viruses, bacteria, spirochete and non-infective etiologies such as atopy and autoimmune causes have also been investigated.^[8] The epidemiological evidence for a possible infective etiology consists of the following^[9]

- 1- Seasonal variation in incidence.
- 2- The occurrence of mild prodromal symptoms.
- 3- The strong association with recent upper respiratory tract infection preceding the cutaneous rash in PR.

Various microorganisms including fungi, spirochetes, streptococci and viruses have been implicated in many studies.^[10,11]

Human herpes virus 6 and 7 have been extensively studied.^[12] some demonstrated active replication of human herpes virus type 6 and type 7 in mononuclear cells of lesional skin as well as identifying the viruses in serum samples of patient including women who experienced miscarriage in association with PR.^[13]

The histopathology of PR characterized by mounds of parakeratosis, Focal spongiosis beneath parakeratosis,

lymphocytic exocytosis, edema of dermal papillae, extravasated erythrocytes, a few melanophages in the papillary dermis, a sparse to moderate superficial perivascular lymphohistiocytic infiltrate with an occasional eosinophil.^[14]

MATERIALS AND METHODS

The aim of this study to evaluate the clinical pattern of pityriasis rosea in Baquba city.

A total number of one hundred patients with various degree of severity, types and distribution of pityriasis rosea were seen in the outpatients clinic department of dermatology in Baquba Teaching hospital, Diyala, Iraq. From January 2017 to October 2017.

All patients were asked about their age, occupation, preceding illness, drug conception, duration of illness, appearance of herald patch, use of irritant during bath.

All patients examined thoroughly to determine the site, shape, severity of the lesions. And screened for syphilis by VDRL (venereal disease research laboratory) to exclude syphilis.

RESULTS

A total number of one hundred patients aged from 9 months to 63 years with mean age of 21years.52 males' patients with mean age 22 years and 48 females' patients with mean age 18 years as show in table (1).

Table 1: Number and sex of the patients.

No.	%	Sex
52	52%	Male
48	48%	Female

Most age group between 11-20 years (38 patients) followed by age group 21-30 year (24 patients) as show in table(2).

Table 2: Age groups.

Age group	No. of patients	Male	Female
0 - 10	20	5	15
11 - 20	38	22	16
21 - 30	24	14	10
31 - 40	8	4	4
41 - 50	6	3	3
51 - 60	2	1	1
61 - 70	2	1	1

The herald patch was present in only 67 patients.

The site of herald patch 22% in abdomen,17% in the chest, 16% in the upper limb, in back 13%, thigh 12%,and less in neck, buttock, lion, elbow and near angle of the mouth as show in the table (3).

Table 3: Site of herald patch.

Site	No. of patients	%
abdomen	15	22
Chest	12	18
Upper limb	11	16
Back	9	13
Thigh	8	12
Neck	6	9
Buttock	2	3
Lion	2	3
Elbow	1	1
Near moth angle	1	1

The types of secondary lesions were as follows: 72% scaly erythematous lesion, 20% scaly erythematous and papular lesions, scaly erythematous and bullous1%, papular lesions only 5%, herald lesion 2% and bullus1%.as show in table (4).

Table 4: The type of secondary rash.

Type of lesion	No.
Scaly erythematous macular	72
Scaly erythematous and papules	20
Scaly erythematous and bullous	1
papular	5
Bullous	1
Herald patch only	1

The commonest site for secondary lesion is the trunk (79 patients) followed by upper limbs and lower limbs (18 patients), upper limbs only in (16 patients), neck involved in 14 patients, face involved in 12 patients, the palms and soles involved in only 3 patients.

A generalized rash spreading all over the body is seen in 3 patients. As show in figure (1)

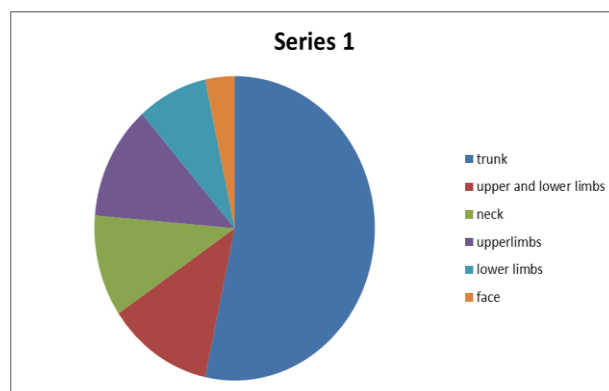


Figure 10: The site of secondary rash.

The total number of site of secondary rash is more than the number of total patients because in one patient there may be more than one site involved.

History of preceding illness is detected in 23 patients, the commonest illness is influenza like illness (22 patients), one patient with gastroenteritis.

Itching was present in 78 patients (15 moderate to severe, mild in 63) and absent in 22 patients as shown in figure (2).

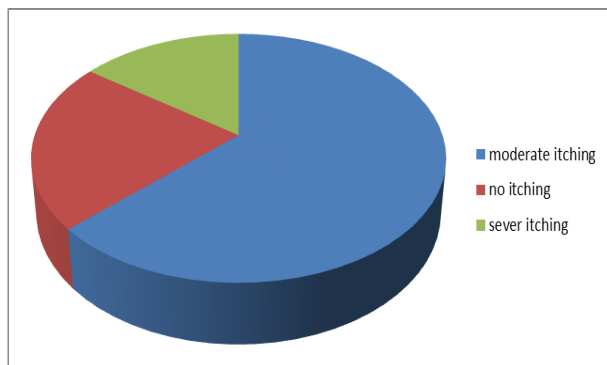


Figure 2: Severity of itching.

DISCUSSION

PR is the commonest papulosequamous skin diseases of unknown etiology, affecting mainly children and young adults.^[2] The incidence is around 0.68 per 100 dermatological patients, or 172.2 per 100,000 person-years. The prevalence in people aged between 10 and 29 years is 0.6%. Evidence on seasonal variation is conflicting, but there is no evidence that the incidence is dependent on mean air temperature, mean total rainfall, or mean relative humidity.^[15] PR begin as small, round papules, which enlarge to form 1–2 cm diameter oval patches with dusky centers and scaly borders. The long axes of the patches often run parallel to the skin lines over the thorax and back, to create a ‘Christmas-tree’ pattern. Occasionally, pityriasis rosea spreads to involve much of the skin surface, including the face and distal extremities. Inflammation may be so intense that some blistering and hemorrhage become clinically apparent. The rash reaches a peak in several weeks and slowly fades over 6–12 weeks.^[16]

In this study male female ratio is 1.08:1 its similar to many other studies.^[2,3,4,18] But in other study the disease more prevalent in female,^[20,15,21] the mean age in this study was 21 years this is nearly compatible with other reports which indicate that most cases occur in young adulthood between age 10 years to 29 years^[16] or 15 year to 40 years^[2] and peak between 10 year to 14 year in.^[17] The incidence of absence of herald patch is 33% is high as compare with other studies such as.^[2] The trunk was found in the present study to be the commonest site involved by secondary rash singly or in combination with other sites, this agreement with other studies^[3,4] only 12% had face involved this agree with most other studies,^[2,3,16] in spite of detailed oral examination done in all patients no one was seen to have oral cavity involvement, although in other study such as Painless oropharyngeal lesions were observed in (28%) and classified as erythematous, macular and papular, erythematovesicular, and petechial lesions.^[21] The itching absence in 22% and 63% mildly itching only

15% had severely itching, this compatible with most other reports.

We conclude that PR in Baquba city is mostly compatible with clinical pattern with other sites in the world and we should be further evaluated by doing long term follow up on larger samples especially those which concern associated with mucosal involvement.

REFERENCES

- Weiss L. Pityriasis rosea - An erythematous eruption of internal origin. *JAMA*, 1903; 41: 20.
- James E. Fitzpatrick, MD Joseph G. Morelli, MD. *Dermatology secrets plus*. 2016. 5th edition. Chapter 3 Inflammatory disorder, 67.
- William D. Jame. Timothy G. Berger. Rik M. Elston. Isaac M. Neuhaus. *Andrews Diseases of the Skin clinical Dermatology*. 12th edition. 2016, chapter 11 Pityriasis Rosea, Pityriasis Rubra Piliaris, and Other Papulosequamous and Hyperkeratotic Diseases, 199.
- Bjornberg A, Hellgren L. Pityriasis rosea: A statistical clinical and laboratory investigation of 826 patients and matched healthy controls. *Acta Derm Venereol Suppl (Stockh)*, 1962; 42: 1-68.
- Garcia e Silva L, Gardner PS. Pityriasis rosea: A virological study. *Br J Dermatol*, 1968; 80: 514-5.
- Kestel JL Jr. Oral lesions in pityriasis rosea. *J Am Med Assoc*, 1968; 205: 597.
- Chuh A, Chan H, Zawar V. Pityriasis rosea - evidence for and against an infectious aetiology. *Epidemiol Infect*, 2004; 132: 381-90.
- Sharma PK, Yadav TP, Gautam RK, Taneja N, Satyanaryana L. Erythromycin in pityriasis rosea: A double blind, placebo controlled clinical trial. *J Am Acad Dermatol*, 2000; 42: 241-4.
- Chuang TY, Perry HO, Ilstrup DM, Kurland LT. Recent upper respiratory tract infection and pityriasis rosea: A case-control study of 249 matched pairs. *Br J Dermatol*, 1983; 108: 587-91.
- Raskin J. Possible dermatropic virus associated with pityriasis rosea. *Acta Derm Venereol*, 1968; 48: 474-81.
- Aoshima T, Komura J, Ofuji S. Virus-like particles in the herald patch of pityriasis rosea. *Dermatologica*, 1981; 162: 64-5.
- Pityriasis rosea: an update with a critical appraisal of its possible herpesviral etiology. *J Am Acad Dermatol*, 2009; 61(2): 303-18.
- Drago F. Evidence of human herpesvirus-6 and 7 reaction in miscarrying women with pityriasis rosea. *J Am Acad Dermatol*, 2014; 71: 198-199.
- Mowafak Hamodat. In James W Patherson. *Weedon's skin pathology*. 4th edition, 2016 Skin nontumor Spongiotic dermatoses. Pityriasis.
- Chuh A1, Lee A, Zawar V, Sciallis G, Kempf W. Pityriasis rosea--an update. *Indian J Dermatol Venereol Leprol*, 2005 Sep-Oct; 71(5): 311-5.
- Bernard A. Cohen, *Papulosequamous Eruptions in Pediatric Dermatology (Fourth Edition)*, 2013.

17. Olumide Y. Pityriasis rosea in Lagos. *Int J Dermatol*, 1987 May; 26(4): 234-6.
18. Sushma Hosamane, Muktha Pai, Thoppil Reba Philipose, and Umaru Nayarmoole. Clinicopathological Study of Non-Infectious Erythematous Papulosquamous Skin Diseases. *J Clin Diagn Res.*, 2016 Jun; 10(6): 19–22.
19. Chuh AA, Lee A, Zawar V. Pityriasis Rosea – an update. *Indian J Dermatol Venereol Leprol*, 2005; 71(5): 311–14.
20. Ayanlowo O1, Akinkugbe A, Olumide Y. The pityriasis rosea calendar: a 7 year review of seasonal variation, age and sex distribution. *Nig Q J Hosp Med.*, 2010 Jan-Mar; 20(1): 29-31.
21. Ciccarese G, Broccolo F, Rebora A. Oropharyngeal lesions in pityriasis rosea. *J Am Acad Dermatol*, 2017 Nov; 77(5): 833-837.